RV Infarction: Review of Physiology and Management

Christopher B. Overgaard, MD, MSc, FRCPC
Medical Director, Coronary Intensive Care Unit
Interventional Cardiologist
Peter Munk Cardiac Centre,
University Health Network
Toronto, Ontario, Canada

Learning Objectives:

1) Review basic pathophysiology of RV infarction

2) Discuss practical management principles for RVI

CASE:

- **48 yo male, DM II, HTN, hyperlipidemia**
- **C/O sudden chest pressure, diaphoresis, went to ER at community hospital**
- PE: **BP 80/50 mmHg**, **HR 50 BPM**, O_2 saturation is 93% on 100% O_2 by face mask.
- Chest: clear lung fields
- JVP 6 cm above the sternal angle and appears to increase during inspiration
- Cardiac : soft 1/6 pan-systolic murmur heard best at lower-right sternal border +S3

ECG

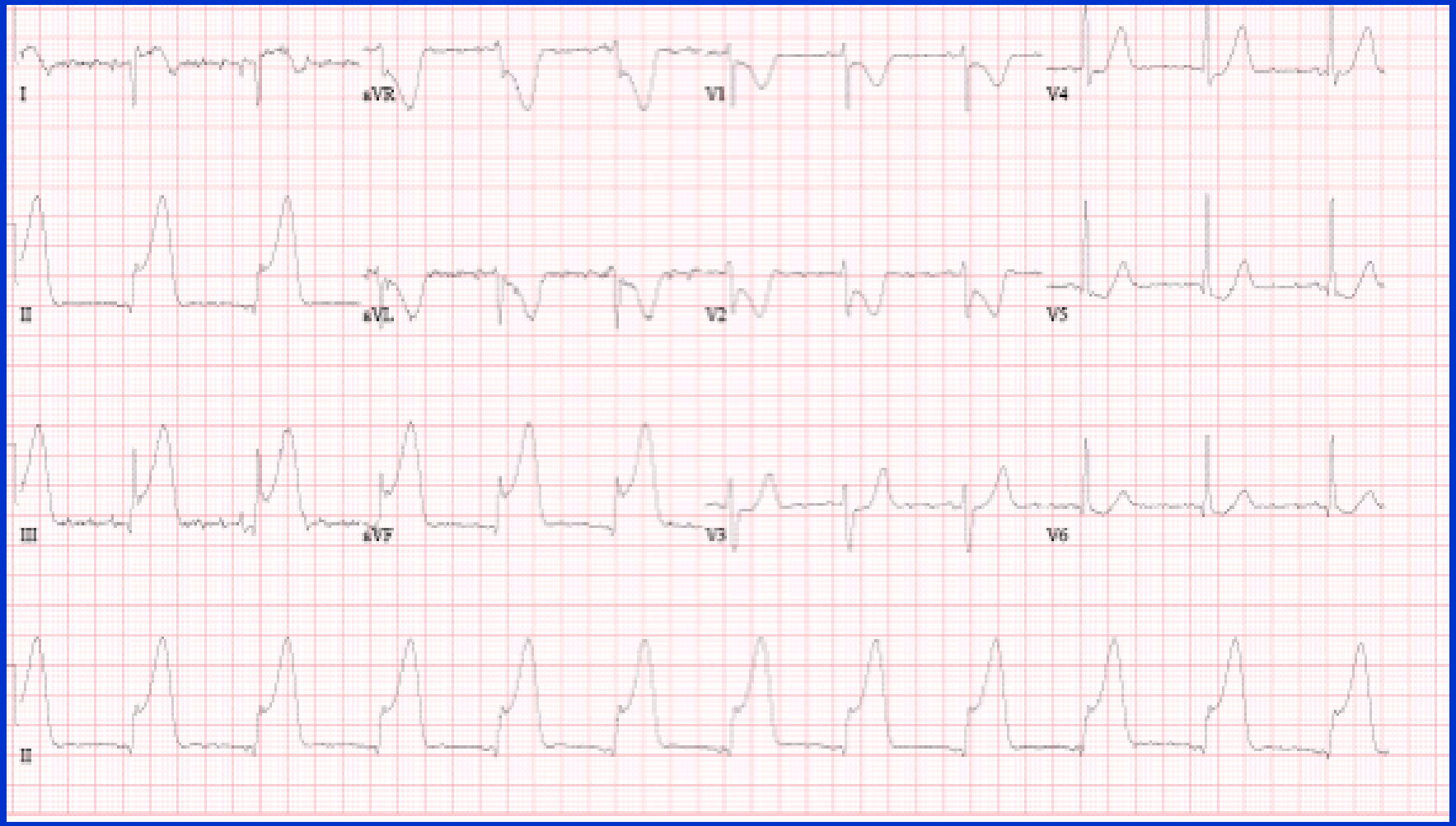

V4R ECG

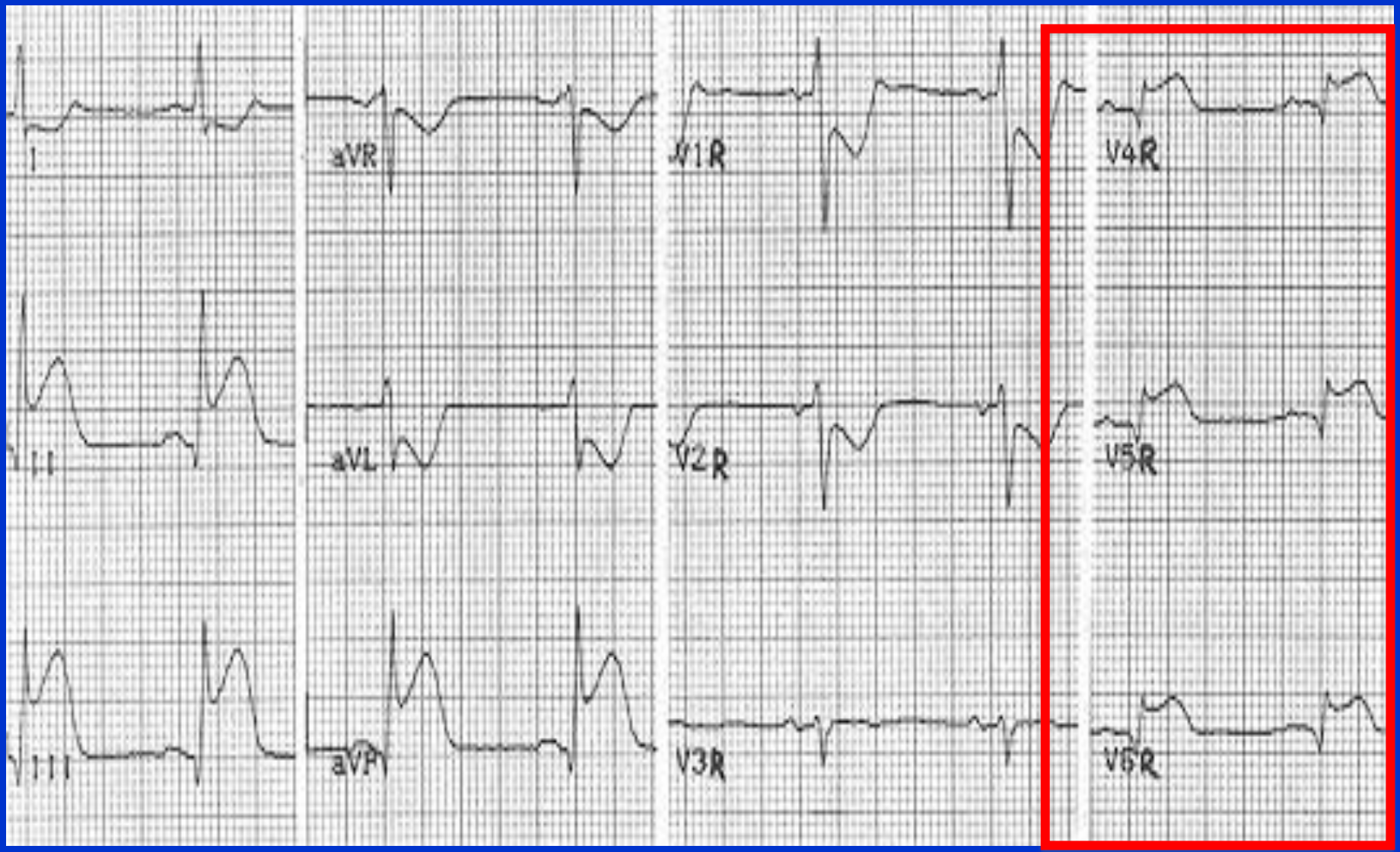

Right Ventricular Function

- thin, small tissue mass
- receives coronary perfusion during both systole and diastole
- Good collateral circulation from left system
- more favorable oxygenation supply-demand characteristics → relatively resistant to ischemia

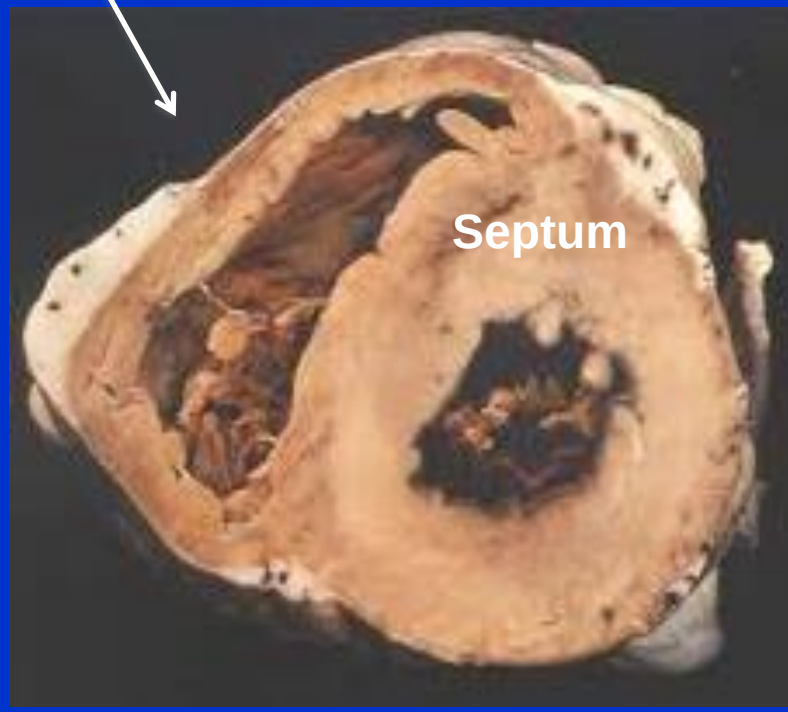

Goldstein JA Prog Cardiovasc Dis 1998;40:325-41.

Right Ventricular Infarction

- ~ 50% of patients with acute transmural inferoposterior left ventricular myocardial infarction (MI) involves RV

Proximal occlusion of the right coronary artery (RCA) prior to the origin of the RV branch for hemodynamically significant RVI

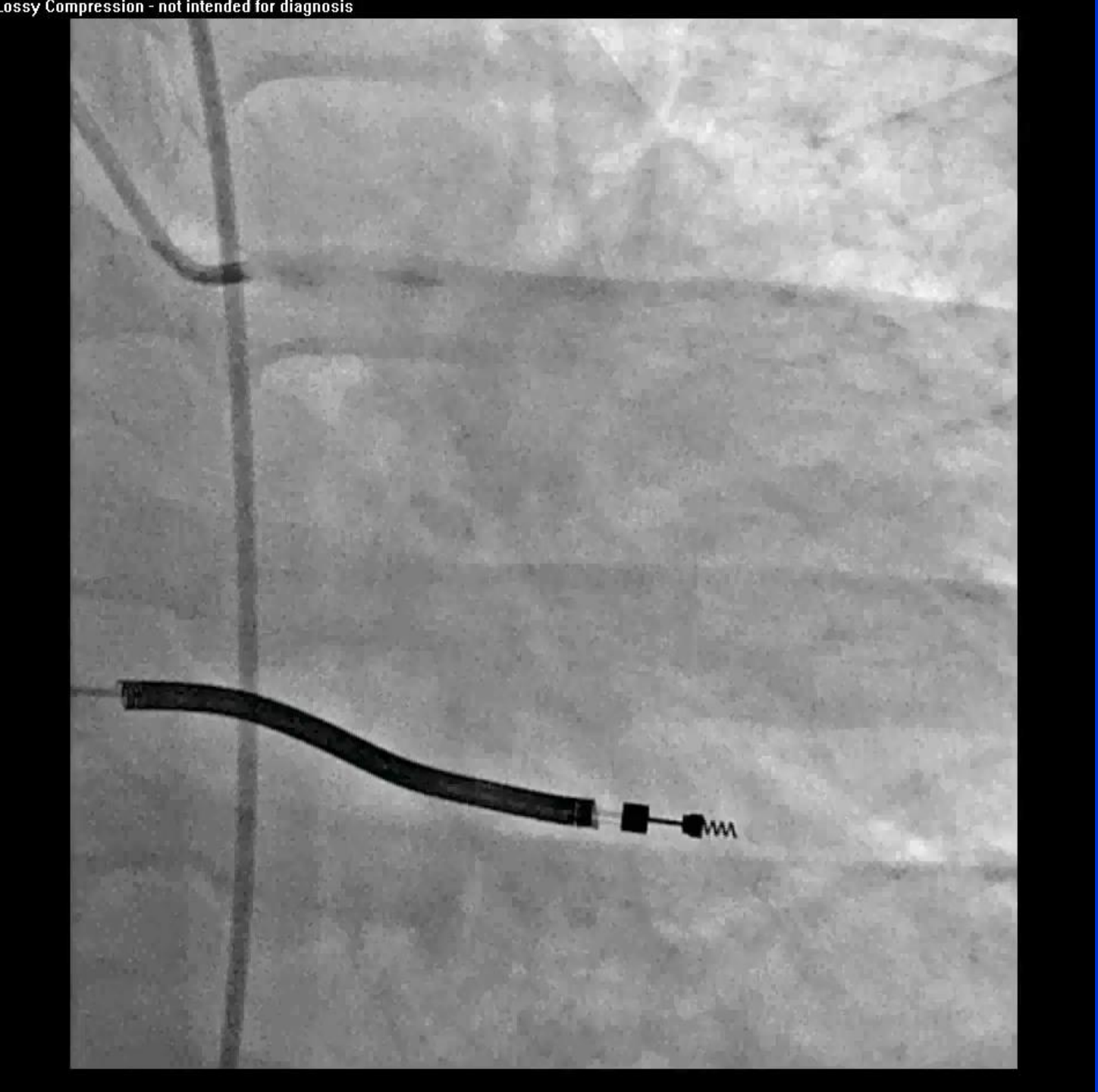

Circumflex occlusion with a left-dominant coronary circulation may also be responsible (rare)

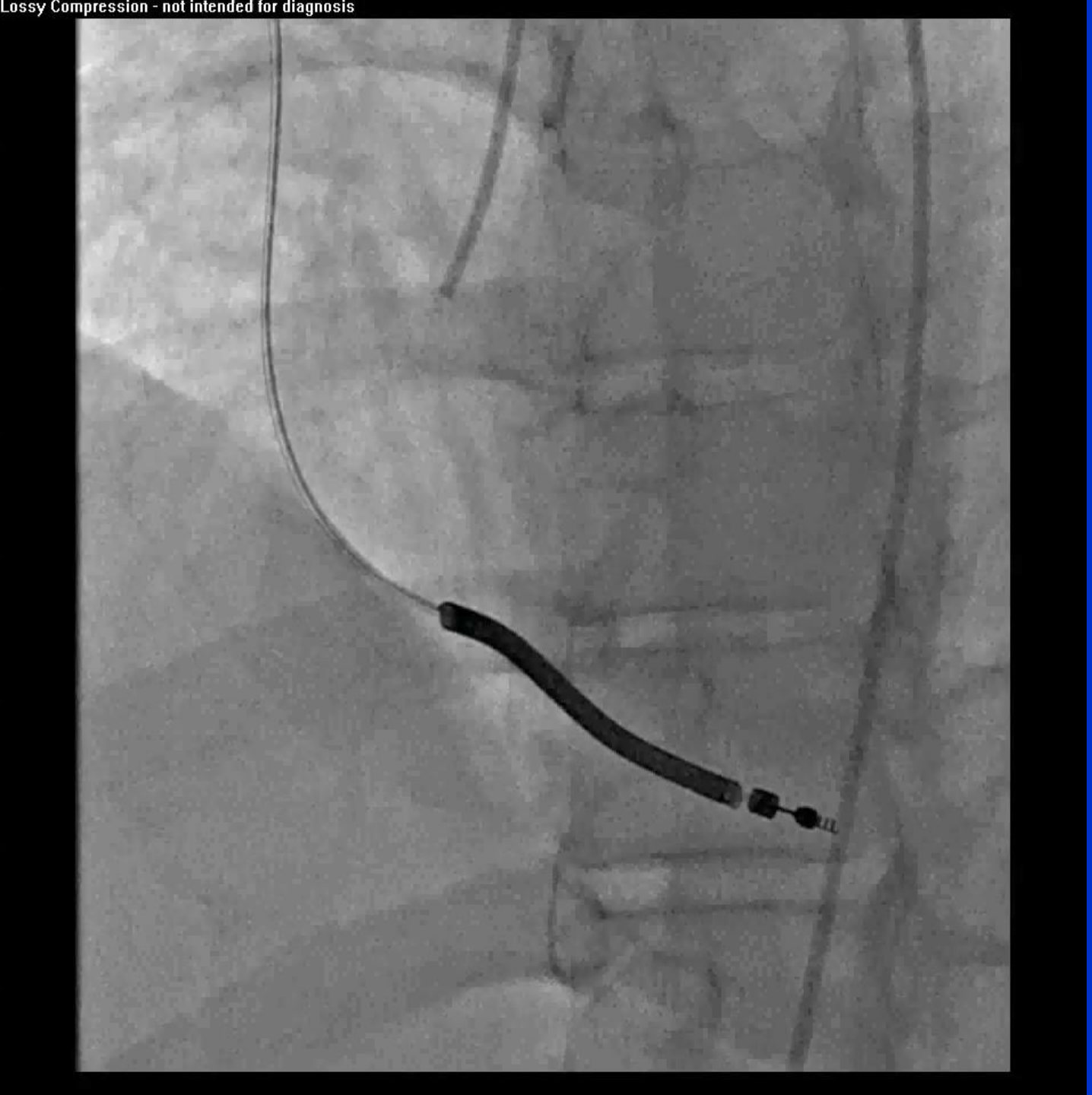

Non dominant RCA may partially or completely perfuse the RV

Causes of Cardiogenic Shock

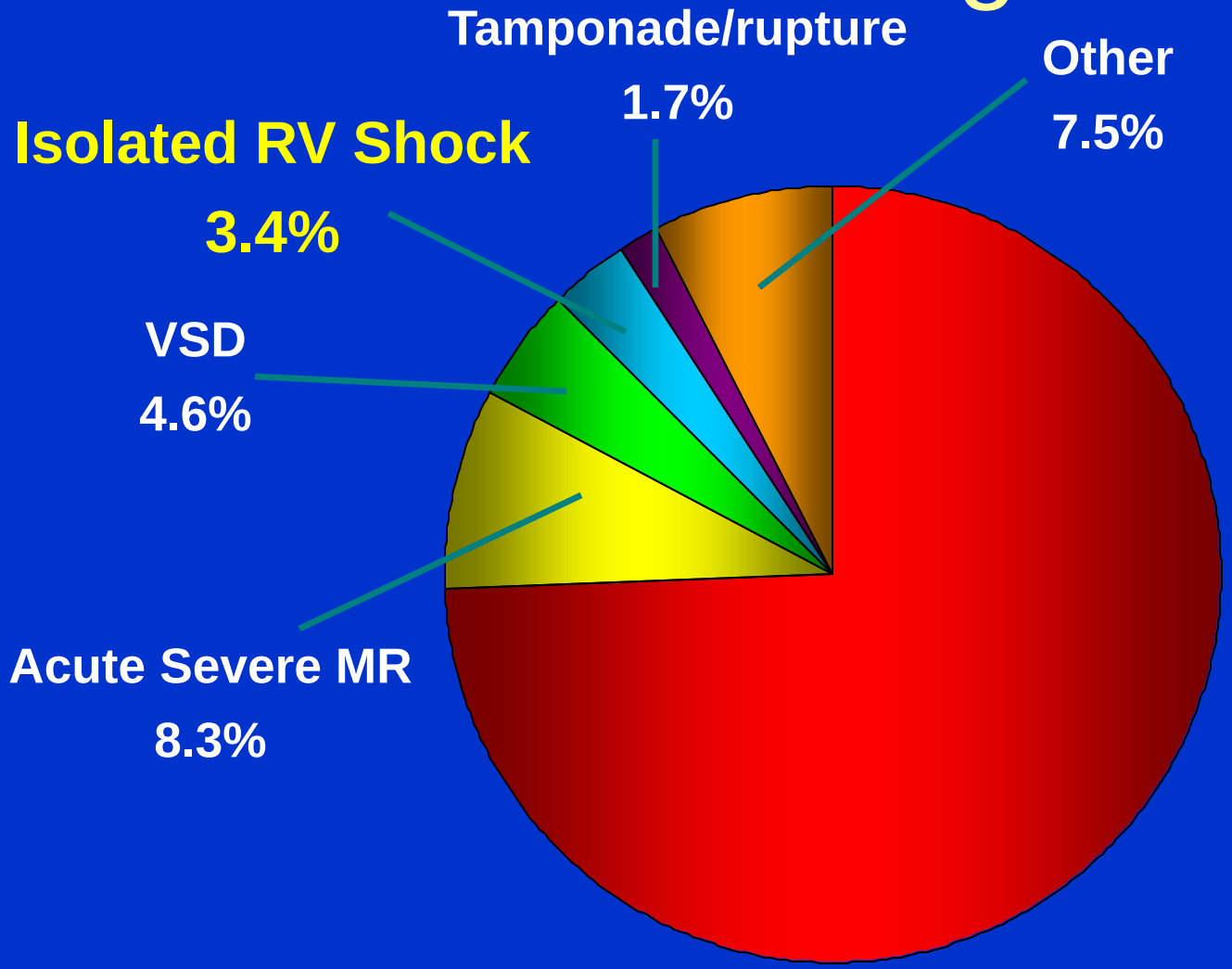

Shock Registry JACC 2000 35:1063

Right Ventricular Infarction: Pathophysiology of Low Output

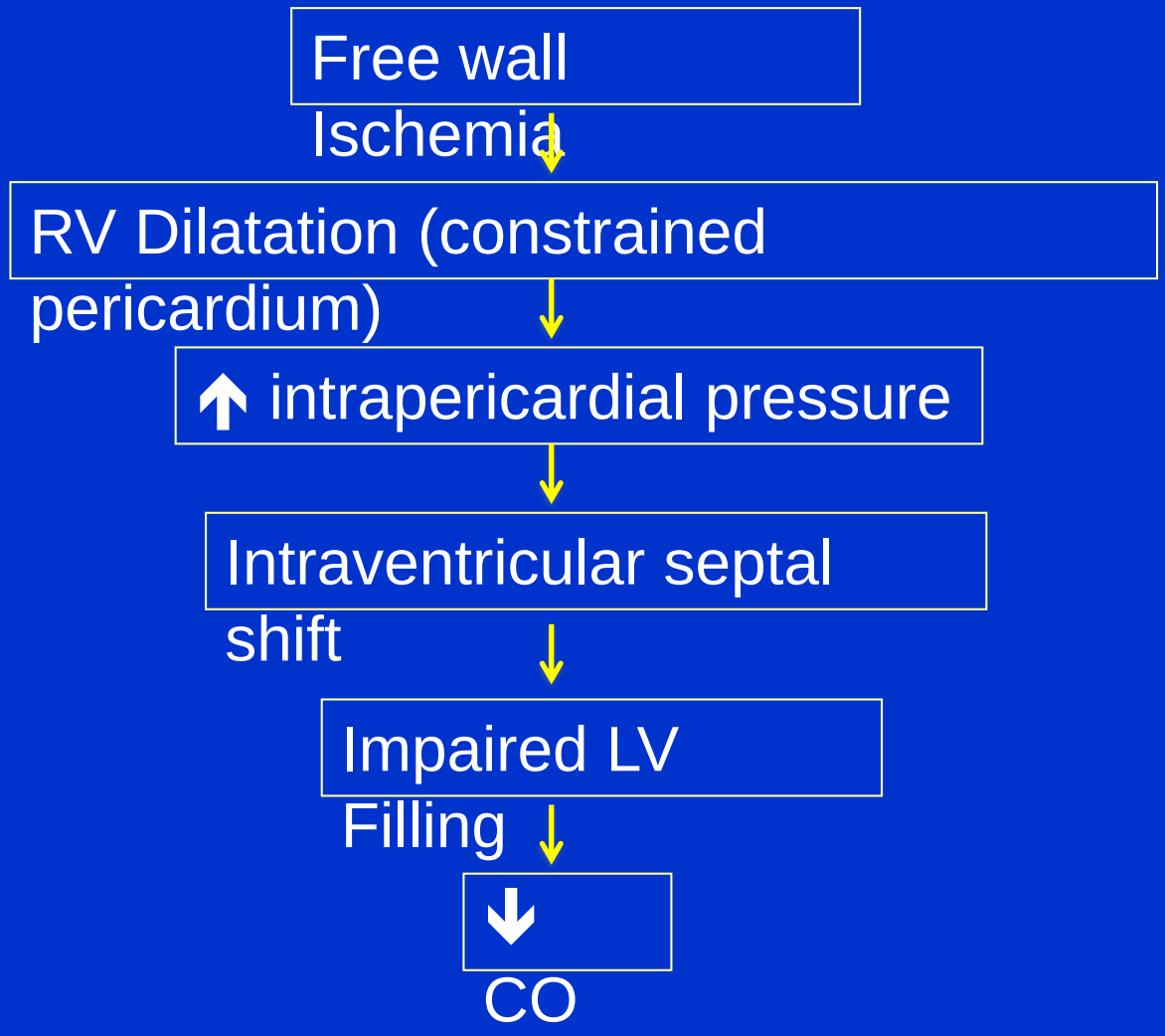

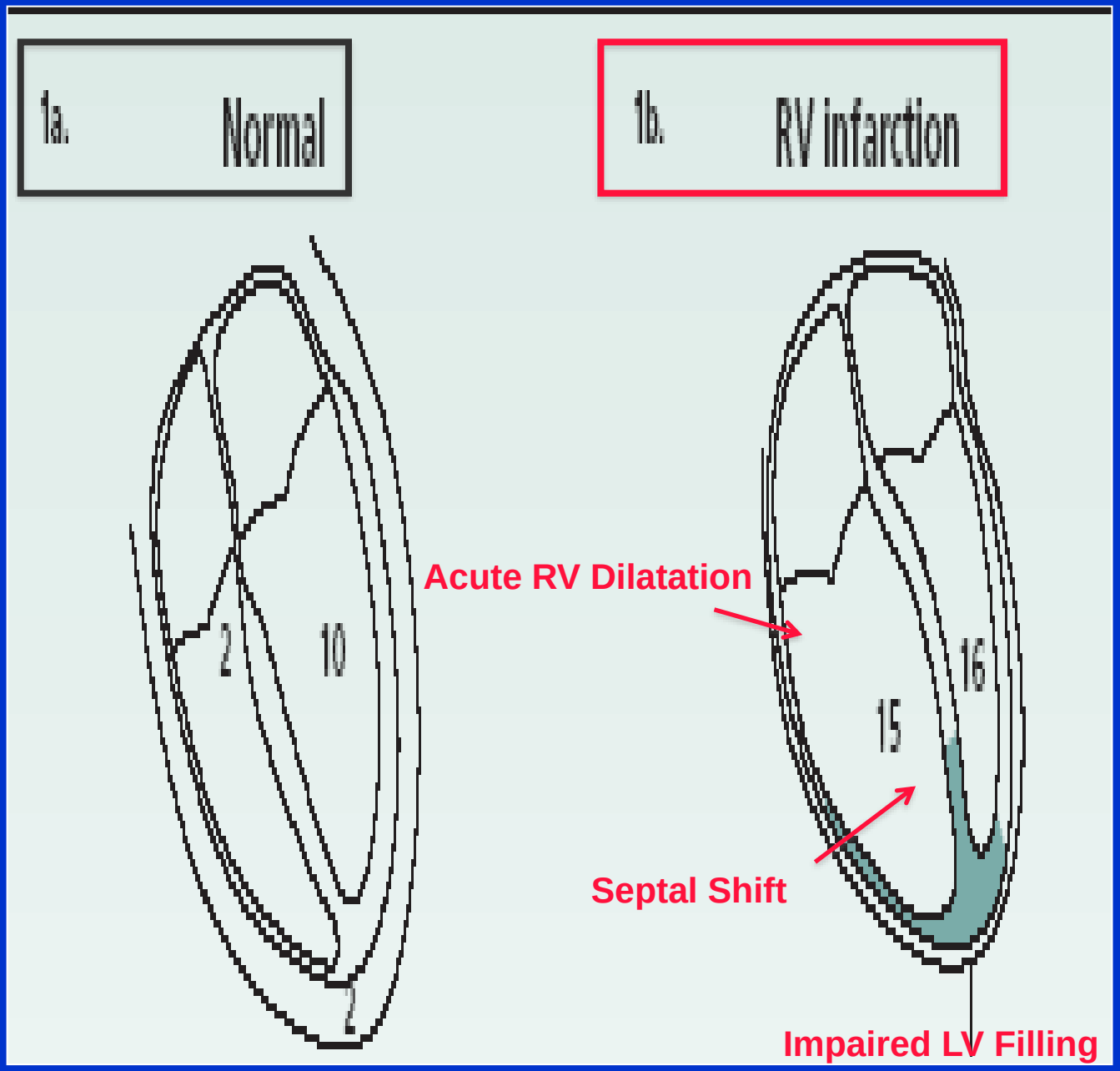
1a. Normal
1b. RV infarction
2
10
2
15
16
Acute RV Dilatation
Septal Shift
Impaired LV Filling

RV Infarction: Diagnosis

Clinical Findings

- Classic Clinical triad :
  1. arterial hypotension
  2. ↑ JVP (esp with +ve Kussmaul's sign)
  3. clear lung fields

- +S3 or +S4 from the right heart

- TR murmur

- Unexplained hypotension or marked hypotension with vasodilator therapy

ECG – V4R

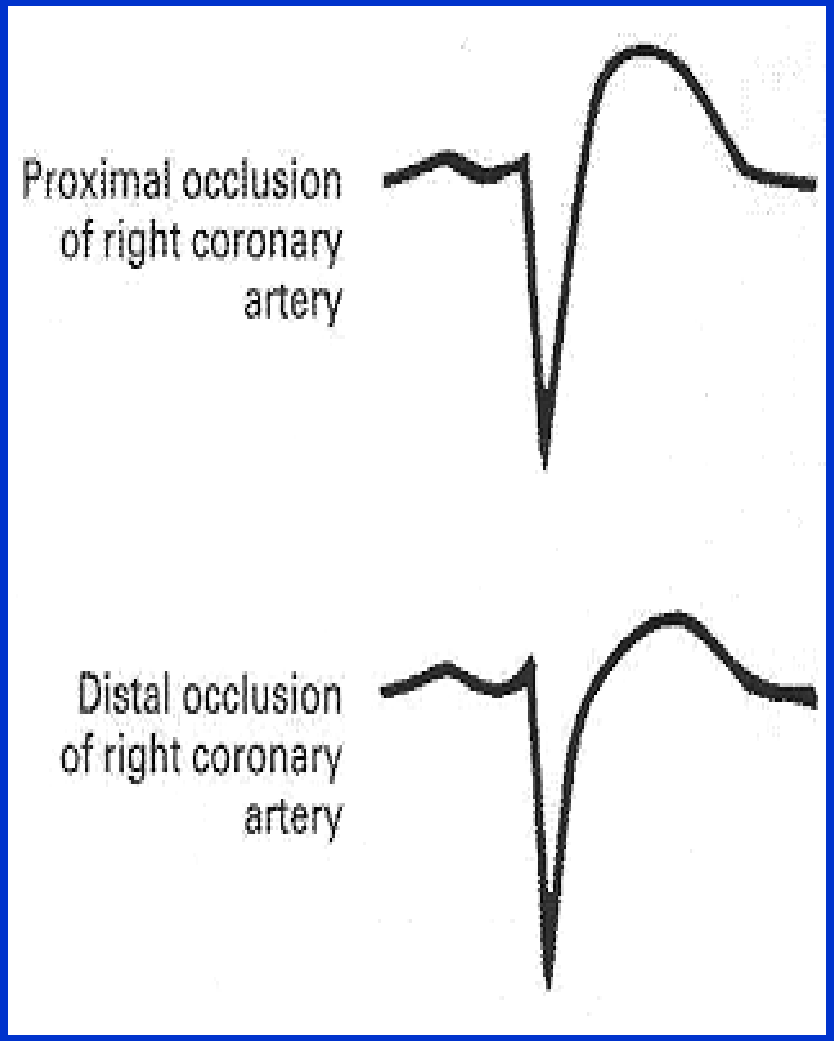

- >1 mm ST-segment elevation present in V4R (+ inferior wall MI) has ~80% accuracy to predict RV involvement
- V4R elevation strong independent predictor of in-hospital mortality and serious complications in patients with IMI
- ***transient*** phenomenon that may be absent in >50% of patients after 12 hours

Zehender *et al* NEJM 1993;328:981-8.

Echocardiography

- valuable initial tool for hypotensive patient with inferior wall MI

- Important echocardiographic signs:
  - RV dilatation
  - segmental wall motion abnormality RVFW
  - paradoxical septal motion
  - TR
  - tricuspid papillary muscle rupture
  - dilated IVC
  - right-to-left interatrial septal bowing **(suggests RA infarction)**
  - and R→L shunting across a patent foramen ovale (PFO)

Otto CM. The Practice of Clinical Echocardiography 1997:2001-2.

Lossy Compression - not intended for diagnosis

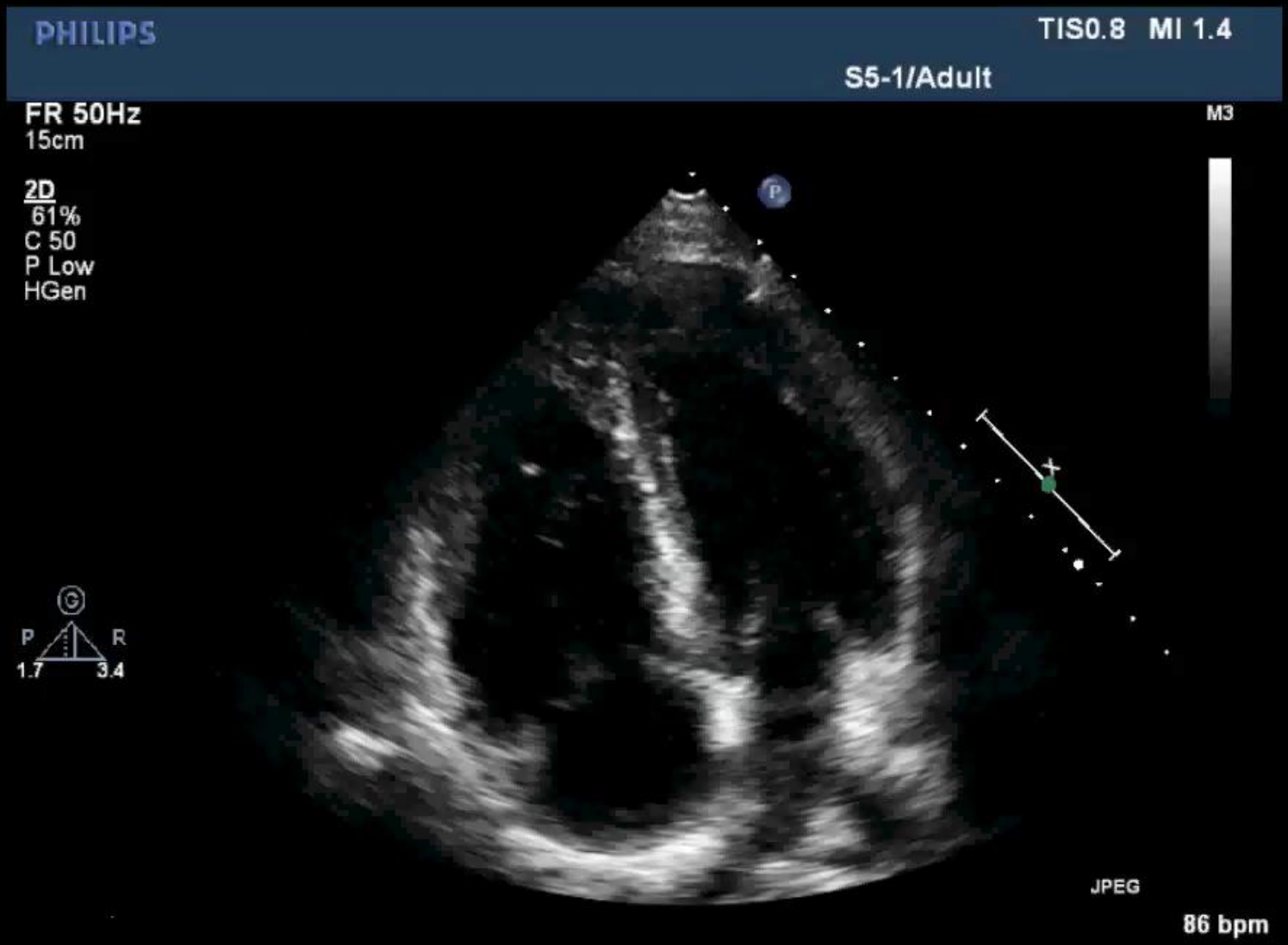

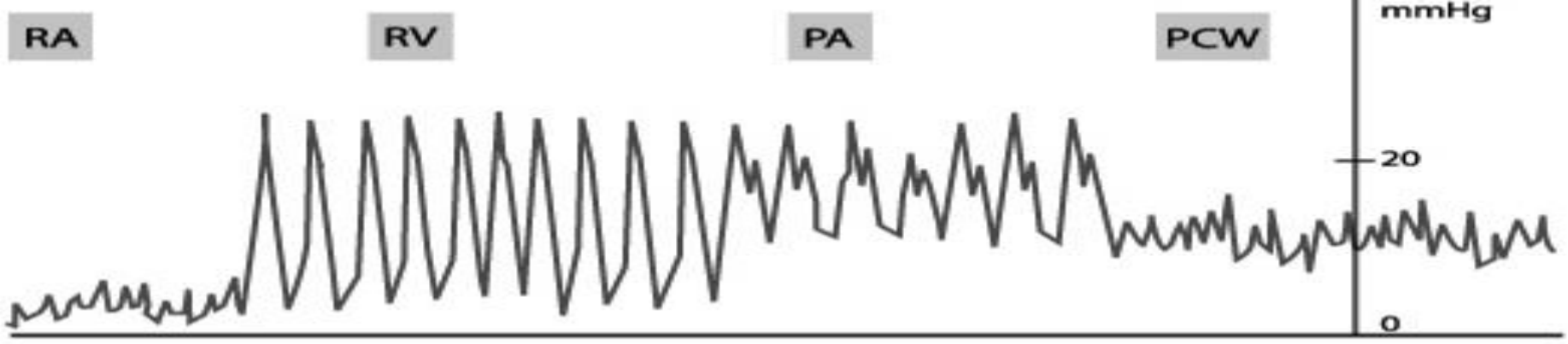

↑↑ RAP
~15-20 mmHg

↑↑ RVEDP
RVSP N to ↓
(Narrow RV PP)

PAP N to ↓

RAP ≈ PCWP
~15-20 mmHg

↓ CO

RVI confirmed when the RAP is >10 mm Hg and the ratio of RAP to PCWP exceeds 0.8 (normal ratio < 0.6)

RV Infarction: Management Principles

1) Optimization of Preload

- RVI patients need adequate filling
- vasodilators and diuretics must be avoided
- small volume challenge (preferably with central venous monitoring) appropriate (~500 cc) to ensure RV is adequately filled

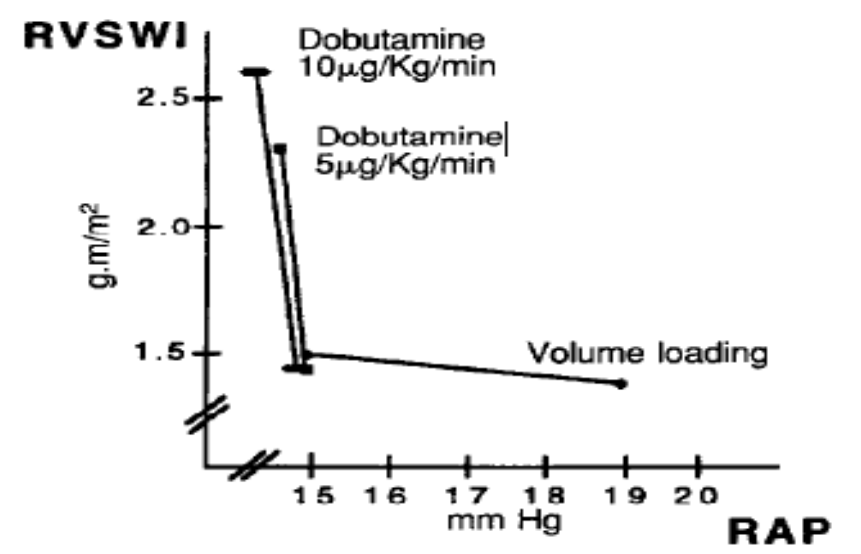

neutral or deleterious effect of excessive volume

Ferrario M *et al* Am J Cardiol 1994:74:329-33

Optimal CVP → 15 mm Hg or RAP /PCWP equilibrium

2) Inotrophic-Vasopressor Support

- For the hypotensive patient with RVI, inotropes should be initiated immediately if no improvement in BP with rapid 500 ml bolus of NS

- Ischemic RV dysfunction, **DOBUTAMINE** shown to significantly improve myocardial performance (↑septal and RVFW contractility)

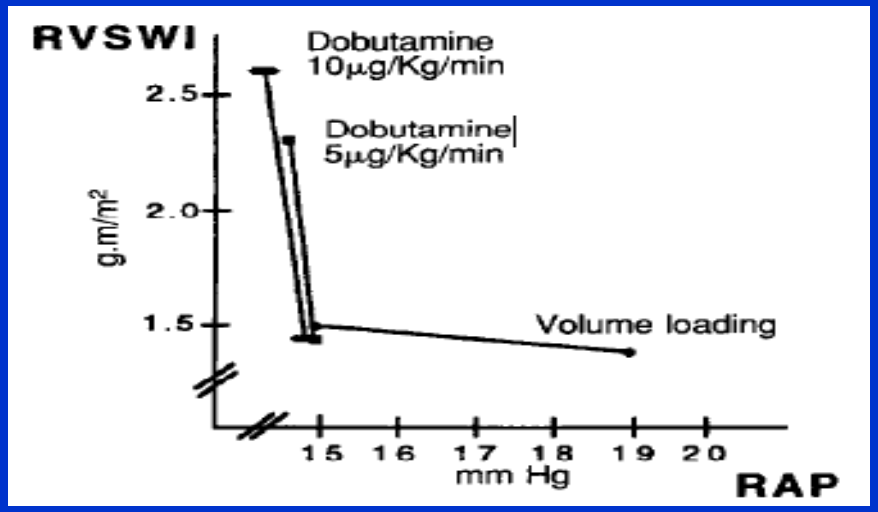

**BEWARE vasodilating properties of Dobutamine and Milrinone **

3) Rhythm Optimization

- Loss of AV synchrony from AV block or atrial fibrillation may precipitate severe hemodynamic compromise in patients with RVI
- Atrial Fibrillation → prompt D/C cardioversion
- AV dysynchrony (2nd degree or complete heart block) → **AV sequential pacing**

RVI Patient with rapid shock

Atrial pacing : SBP from 85→125 mmHg

CO improved with resolving lactate etc.

4) Reperfusion Therapy

1) Thrombolysis:

- inferior wall infarction + RVI 4.2x lower mortality rate with successful thrombolysis
- hypotension reduces the success of thrombolysis [1]

2) PPCI:

- first line therapy where available

1 Zehender *et al* JACC 1994:24:362-9.

Lossy Compression - not intended for diagnosis

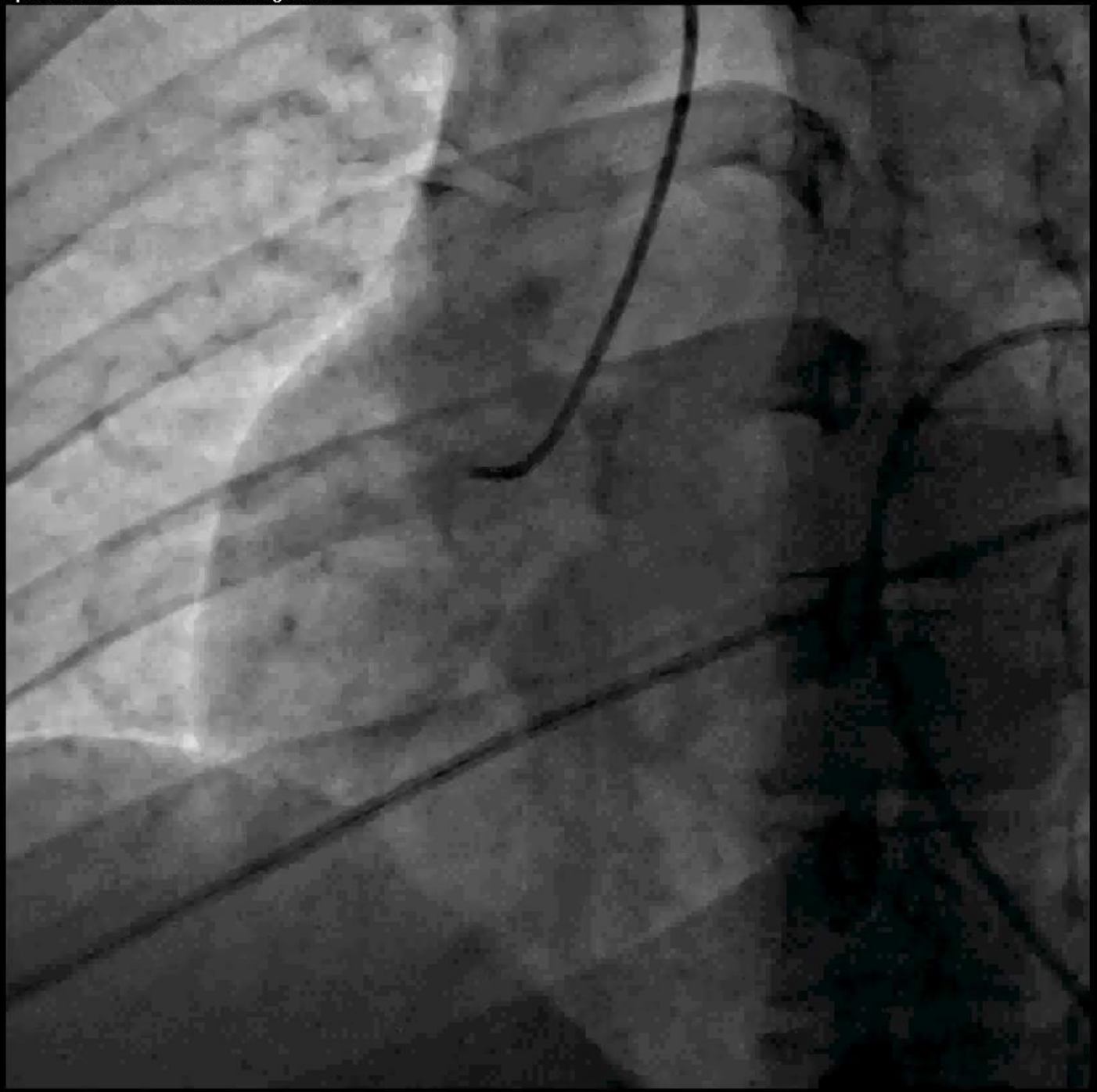

Lossy Compression - not intended for diagnosis

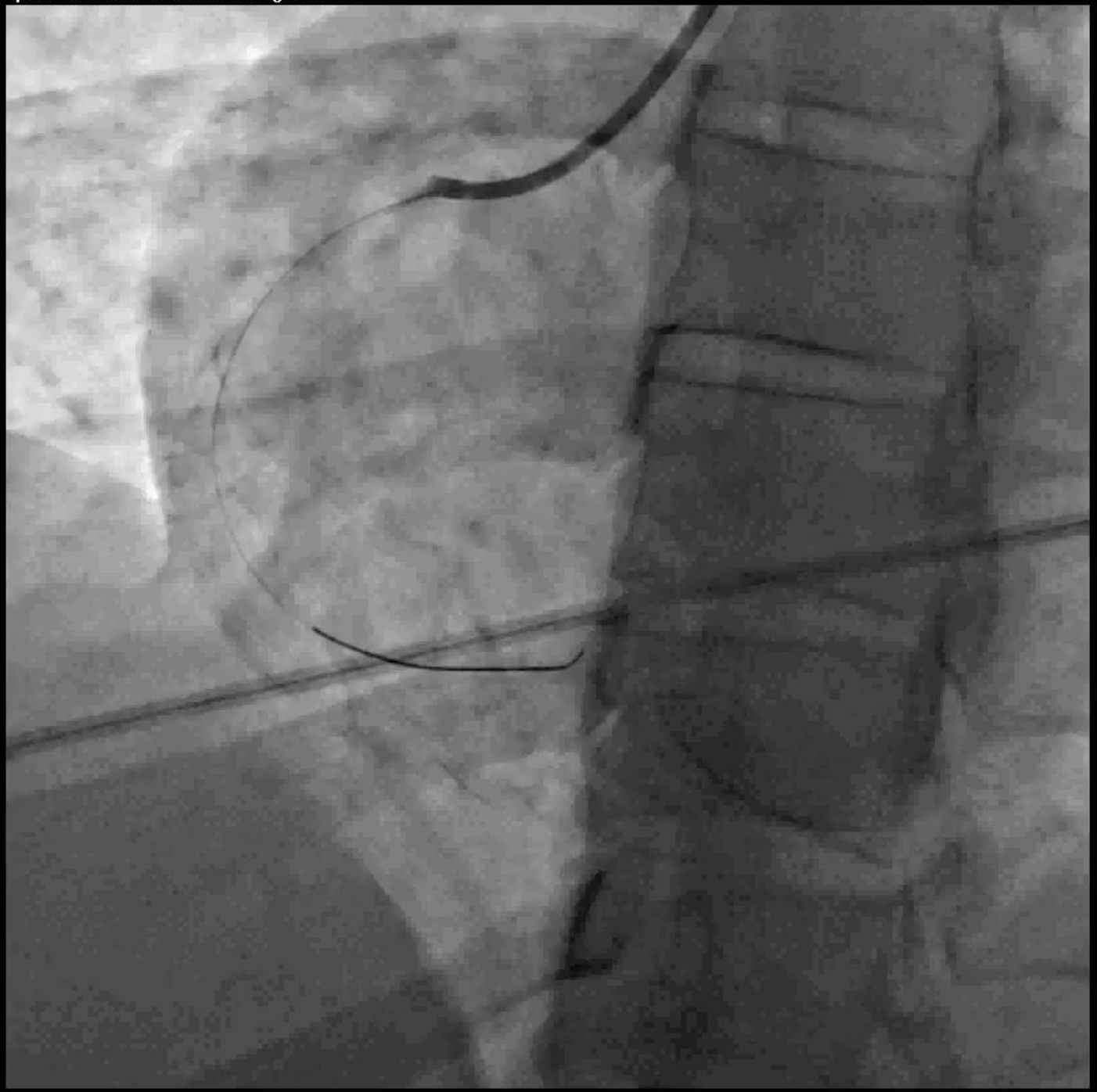

Lossy Compression - not intended for diagnosis

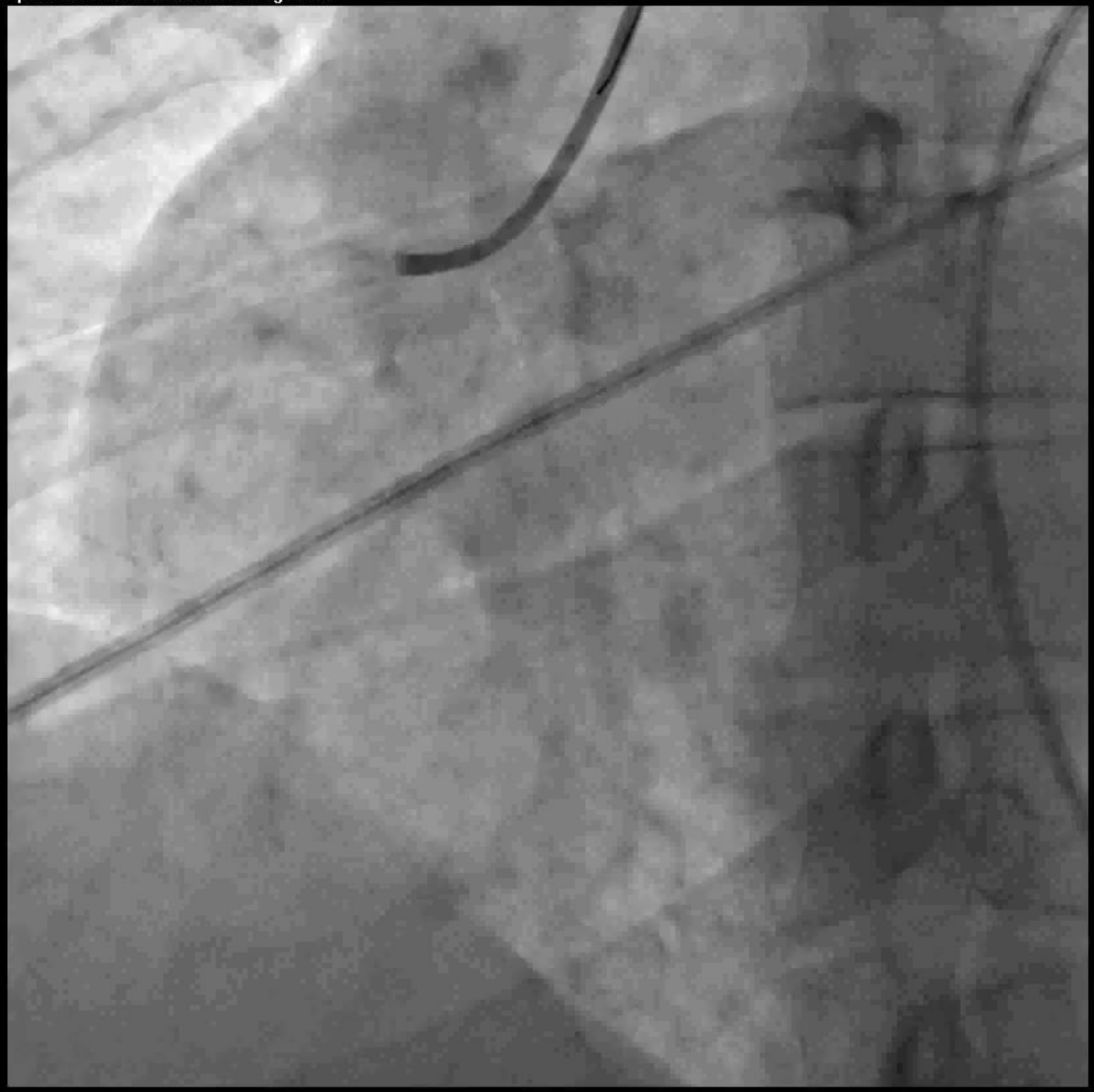

5) Mechanical Circulatory Support

1) Intra-aortic balloon counter pulsation (IABP):

- Theoretical improvement in coronary perfusion pressure and LV performance

2) Centrimag or Right Sided Impella

- For refractory shock

Complications of RVI

1) Ventricular septal defect (VSD)

- very poor prognosis
- VSDs tend to be complex (multiple irregular and variable interventricular connections), usually located at the inferobasal portion of the septum

2) Hypoxemia

- Unexplained hypoxemia unresponsive to O_2 in the setting of RVI: consider R→L shunt through PFO
  - shunt will be reduced with an improvement in RV function

3) Pulmonary embolism (PE)

- rare complication described in the setting of RVI
- mural thrombus formation due to extensive RVFW akinesis and dilatation

Prognosis

- RVI = high in-hospital mortality and CV complication rates
- prospective study of 200 consecutive patients admitted with acute inferior wall MI, patients with RVI had an in-hospital mortality rate of 31% as compared to 6% with no RV involvement [1]
- Major in-hospital complication rates (cardiogenic shock, complete heart block, and VF) were 64% with RVI, 28% without RVI
- Survival of early complications → spontaneous clinical improvement 3 to 10 days after event[2]

1. Zehender *et al* JACC 1994:24:362-9.
2. Bueno H *et al* JACC 2001;37:161A

Conclusions

- Right ventricular infarction (RVI) common with inferior infarction and carries an increased complication and mortality rate
- **Cardiogenic shock** due to RVI is relatively uncommon complication, but should be recognized early
- Early hemodynamic and mechanical support + PCI can lead to a good recovery and long-term prognosis
- near normal RV function can be restored even after prolonged ischemic insult***: "reversible clinical entity"***